



## **Evaluation Effectivity Anti-Rheumatoid Arthritis of Hydroethanolic Extract *Ageratum conyzoides* L. Leaf in Complete Freund's Adjuvant-Induced Arthritis Rats**

Erna Harfiani <sup>1</sup>, Katrin <sup>2</sup>, Ade Arsianti <sup>3</sup>, Anton Bahtiar <sup>4\*</sup>

### **Abstract**

**Introduction:** *Ageratum conyzoides* L. is widely available in Indonesia and has been used for the treatment of inflammatory cases as one of Indonesian traditional medicine and also in many countries for a long time. Rheumatoid arthritis is a chronic inflammatory autoimmune disease which mainly attacks the joints. **Materials and Methods:** There are 3 levels doses of the hydroethanolic extract of *Ageratum conyzoides* L. leaf (40, 80, 160 mg/200 g bw), a saline solution as normal control and methotrexate as a positive control that provided orally in this observation. Arthritis was induced by injecting complete Freund's adjuvant (CFA) subcutaneously into the left hind paw. Paw edema volumes were observed on the day of injection and weekly observed until day 28 to ensure the successful induction. The treatments applied on day 29 and observation using plethysmometer on day 29, 36, 43 and 50. Histopathology was performed to observe for synovitis score in ankle joints of rats on day 50. The anti-rheumatoid arthritis effectivity of the *A. conyzoides* leaf extract was assessed based on the ability to reduce the paw edema volumes and synovitis score in rats. **Results and Discussion:** The oral treatment of the *A. conyzoides* leaf extract (40, 80 and 160 mg/200 g bw) showed a significant reduction ( $P < 0.05$ ) in paw edema volume in rats on day 50 when compared to arthritis control rats. The *A. conyzoides* leaf extract (80 and 160 mg/200 g bw) also cause a reduction in synovitis score in rats when compared to arthritis control rats. Allegedly, flavonoids from the extract play an important role in reducing the activity and production of pro-inflammatory cytokines, especially TNF- $\alpha$  and IL-1 in the mechanism for its anti-rheumatoid arthritis effects. **Conclusions:** The observation results demonstrated the potential beneficiary effect of the *A. conyzoides* leaf extract in rats. This study supports the traditional use of *Ageratum conyzoides* for the treatment of rheumatoid arthritis.

**Keywords:** *Ageratum conyzoides* L., Anti-rheumatoid arthritis, Complete Freund's adjuvant, Rats, Flavonoids

---

<sup>1</sup> M.D., Graduate Program of Herbal Medicine, Faculty of Pharmacy, Universitas Indonesia, Indonesia

<sup>2</sup> Ph.D., Lecturer, Laboratory of Phytochemistry and Pharmacognosy, Faculty of Pharmacy, Universitas Indonesia, Indonesia

<sup>3</sup> Ph.D., Lecturer, Departement of Medicinal Chemistry, Faculty of Medicine, Universitas Indonesia, Indonesia



<sup>4\*</sup> Ph.D., Lecturer, Laboratory of Pharmacology, Faculty of Pharmacy, Universitas Indonesia, Indonesia

**\*Corresponding author:** Faculty of Pharmacy, Universitas Indonesia, Indonesia.

Email : anton.bahtiar@gmail.com

## 1. Introduction

Rheumatoid arthritis (RA) is a chronic inflammatory autoimmune disease, which mainly attacks the joints and causes proliferation of the synovium, cartilage degradation, and bone erosion. Previous studies have shown pro-inflammatory cytokines, such as tumor necrosis factor-alpha (TNF- $\alpha$ ) and interleukin-1 (IL-1) plays a crucial role in the process of RA erosion (Ikawati, 2014; Rosenbergh, 2013). RA is characterized by chronic inflammation, as a response of the immune system to protect the body from injury or attack, such as microorganisms, or other causes. Inflammation is a complex reaction involving the enzyme activation, cytokine production, fluid extravasation, the influx of inflammatory cells, tissue damage and repair processes of the body. Approximately 1-2% of the world population suffer from RA and led to a decline in labor productivity, mobility disorders, and increased health care costs. In general, the treatment of RA using drugs known as corticosteroids and NSAIDs (Non-steroidal anti-inflammatory drugs), but these two drugs only alleviate the symptoms and do not cure the disease. Meanwhile, the drug in the DMARD group (Disease-modifying anti-rheumatic drug), i.e Methotrexate, which is currently known as the first-line therapy for the treatment of RA, as empirically shown to inhibit the progression of RA disease (Rosenbergh, 2013; Schuna, 2005). The use of these drugs in the long term can cause

various side effects, such as gastrointestinal disorders (vomiting, nausea, rash, abdominal discomfort, and bleeding) (Aletaha et al., 2003). Therefore, it is important to look for alternative therapies that have the potential activity for the treatment of RA.

*Ageratum conyzoides* L. (Asteraceae) (Babandotan), is a plant that is widely available in the tropics and sub-tropics, such as Africa, Asia, and America (Okunade, 2002; Singh et al., 2013). These plants are used traditionally in Indonesia and the world, as a medicinal plant, especially for diseases associated with inflammation. *A. conyzoides* which widely available in Indonesia and also in other places in the world is expected to be as an alternative or complementary therapy of RA disease (Singh et al., 2013; Moura et al., 2005; Hassan et al., 2012). The purpose of this study was to determine the anti-rheumatoid arthritis activity of the hydroethanolic extracts *A. conyzoides* L. leaf in complete freund's adjuvant-induced arthritis rats.

## 2. Material and Methods

### Plant material and extract preparation

*A. conyzoides* (Babandotan) leaves obtained from the Research Institute for Spices and Medicinal Plants (BALITTRO), Bogor. The extraction method is use cold maceration using 70% ethanol (1:5) to obtain a thick extract [12]. The results were obtained, weighed and stored in dark glass bottles (yield: 16.2% w/w).



### **Induction of arthritis with Complete freund's adjuvant (CFA)**

In this study, as many as thirty Sprague-Dawley rats (175-250 g) induced by complete freund's adjuvant (1 mg / ml; 0,1 ml) in the left hind paw subcutaneously on the first day and given a 28-day waiting period to establish a rat model RA [13], except for the normal control group. Rats were divided into six groups, with each group consisting of five rats. Group I (normal control) and Group II (negative control) by carboxymethyl cellulose (CMC) 0,5%, Group III (positive control) were given methotrexate 0,05 mg / 200 g bw / day orally and group IV, V, VI given the hydroethanolic extract of *Ageratum conyzoides L.* leaf in three variation dosages (40, 80, 160 mg / 200 g bw / day) over a period of 21 days. On day 29, 36, 43 and 50, paw edema volume was measured and then on day 50, the rats were isolated in ankle joint to make preparations to observe the histopathological synovitis score.

#### **Examination of paw edema volume**

Paw edema volume was observed and recorded on day 1 before injection of CFA, and made further observations on days 29, 36, 43 and 50. Measurements were made using plethysmometer. The percentage inhibition of paw edema volume measured on day 50 and the data was analyzed by comparing results among the six groups. The percentage inhibition of paw edema volume was calculated using the following formula =  $[(Vc-Vt) / Vc] \times 100$

Where Vc is the average value of the paw edema volume by control group and Vt is the average value of the paw edema volume by the test group (Awad, et al., 2013).

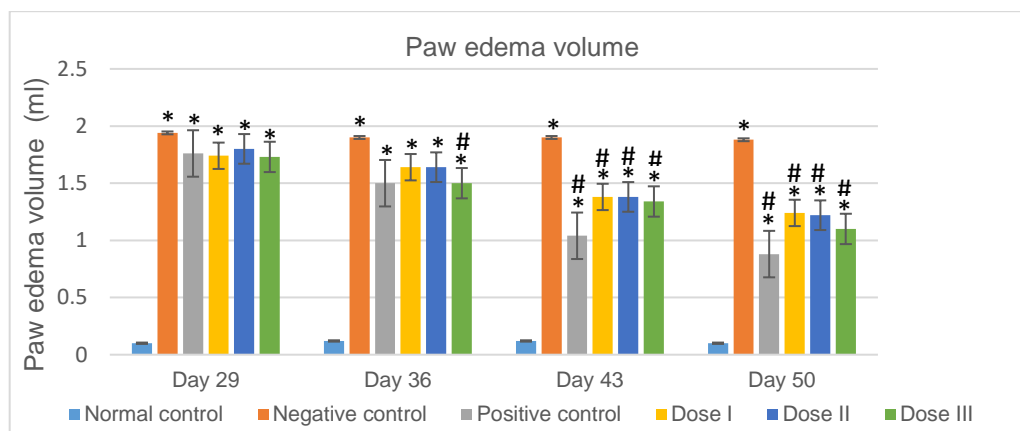
### **Examination score synovitis**

On day 50, the rat's ankle joints were isolated and cut longitudinally (Bolon et al., 2011). Histopathological preparations ankle joints made by means of fixation, decalcification, dehydration, purification, infiltration / embedding in paraffin blocks, and cutting (3-5 m), then by staining hematoxylin-eosin staining (H & E). Histopathologic features joints were observed by two observers using a microscope (40x and 400x). There are three variables were observed in the synovial tissues that are the enlargement of the synovial lining cell layer (0-3 points), the density of the resident cells (0-3 points), and inflammatory infiltrates to assess synovitis score (0-3 points) (Krenn et al., 2006). A results synovitis score 0-1 mean no synovitis, score 2-4 mean low-grade synovitis and score  $\geq 5$  mean high-grade synovitis, closely associated with a rheumatic joint disease.

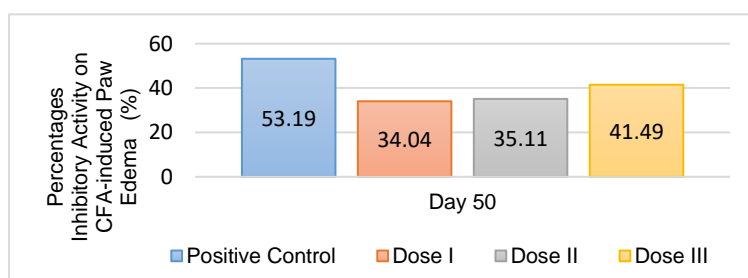
## **3. Results and Discussion**

### **Effect of the *Ageratum conyzoides* leaf extract on the volume paw edema**

Effect anti-rheumatoid arthritis of the hydroethanolic extract of *Ageratum conyzoides L.* leaf on the volume paw edema induced by complete freund's adjuvant (n = 5) is shown in Fig. 1A. Volume paw edema measured by plethysmometer at day 29, 36, 43 and 50. On day 43 and 50, showed that three variation doses of the extract can reduce the paw edema volume was significantly (p <0.05) when compared to the negative control. Percentage inhibition of paw edema at day 50 gives a yield of 34.04% at the first dose, 35.10% at the second, 41.49% at third doses and 53.19% at the positive control (Fig 1B).



**Figure 1A.** Anti-rheumatoid arthritis activity of the hydroethanolic extract of *Ageratum conyzoides L.* leaf on CFA-induced paw edema in rats on day 29<sup>th</sup>, 36<sup>th</sup>, 43<sup>rd</sup> and 50<sup>th</sup> (\* ) p<0.05 as compared to normal control group; (#) p<0.05 as compared to negative control group

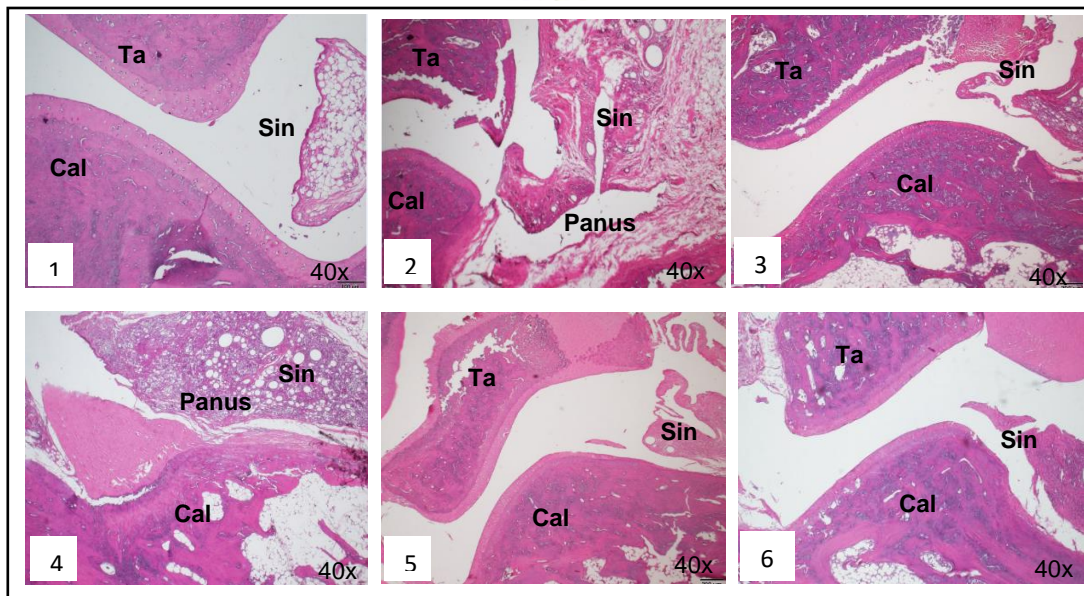


**Figure 1B.** Inhibitory activity of the hydroethanolic extract of *Ageratum conyzoides L.* leaf on CFA-induced paw edema in rats on day 50<sup>th</sup>

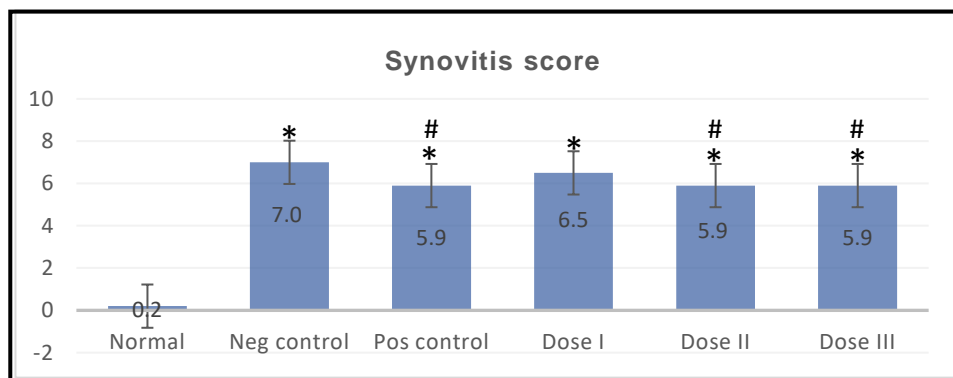
**Effect of the *Ageratum conyzoides* leaf extract on the score synovitis**

Effect anti-rheumatoid arthritis of the hydroethanolic extract of *Ageratum conyzoides L.* leaf from the observation histopathological features of the synovial membrane in a rat ankle joint is shown in Figure 2A. There is a difference between the normal group and the complete freund's adjuvant-injected rat group. In the normal group, there is no synovitis and no degradation of cartilage and bone, while in the complete freund's adjuvant-injected rat group occurs severe

synovitis. Observation synovitis score on the foot ankle joints by histopathology examination in rats induced complete freund's adjuvant showed an increased amount compared with normal control group. Anti-rheumatoid arthritis activity of three dose levels of the *A. conyzoides* leaf extracts proven to reduce synovitis score compared to negative control group. After 21 days of treatment, the results showed synovitis score decreased significantly (p < 0.05) in the dose of 80 and 160 mg / 200 g bw / day of the extract as compared to negative control group. Synovitis scores in each group at day 50 is shown in Figure 2B.



**Figure 2A.** Histopathologic features of the ankle joint synovium in all treatment groups on day 50<sup>th</sup>  
 1= Normal control; 2= Negative control; 3= Positive control; 4= Dose I; 5= Dose II; 6= Dose III; Ta = Talus bone; Cal = Calcaneus bone; Sin= Membrane synovial



**Figure 2B.** Synovitis score in all treatment groups on day 50<sup>th</sup>  
 (\*)  $p < 0.05$  as compared to normal control group and (#)  $p < 0.05$  as compared to negative control group.

## Discussion

The treatment of rheumatoid arthritis (RA) used in the long term cause undesirable toxicity side effects, such as gastrointestinal system disorders hematology, respiratory and hepatotoxic. Research is needed to get a new drug that can be used as an alternative

medicine in the treatment of RA mainly from nature. Plants *Ageratum conyzoides L.* contain secondary metabolites such as flavonoids, tannins, alkaloids, saponins, terpenoids and polyphenols (Singh et al., 2013; Hassan et al., 2012). Quercetin, a member of the flavonoids have been extensively reviewed on its effects on inflammatory processes (Nair et al., 2006).



It is hoped that this plant can also be used as a complementary therapy in the treatment of RA.

In this study, the results obtained that in the positive control (methotrexate) and suspension *A. conyzoides* leaf extract, causes a decline in the average paw edema volume compared with control group, started on day 36 and then the highest volume on day 50. Based on the statistical analysis of the positive control (methotrexate) and dose group I, II and III of the hydroethanolic extract of *Ageratum conyzoides* L. leaf on the 43<sup>rd</sup> and 50<sup>th</sup> can decrease paw edema volume of rats significantly ( $p < 0.05$ ). Activities anti-rheumatoid arthritis of the hydroethanolic extract of *Ageratum conyzoides* L. leaf containing secondary metabolites mainly flavonoids (quercetin) can inhibit the process of chronic inflammation. Quercetin can inhibit the formation and expression of pro-inflammatory mediators, especially TNF- $\alpha$  and IL-1 that played an important role in the anti-inflammatory mechanisms by means inhibition activation of NF- $\kappa$ B (Nuclear Factor kappa B) (Nair et al., 2006). Cytokines TNF- $\alpha$  and IL-1 as pro-inflammatory mediators can stimulate the expression of adhesion molecules in endothelial cells, enhance and mobilize leukocytes, increases the production of other cytokines and eicosanoids. Besides that, flavonoids can inhibit arachidonic acid metabolism through the regulation of the enzyme COX-2 (Cyclooxygenase) in the formation of prostaglandins that decreased vascular permeability (Bellik et al., 2013). Inhibition of the influx of inflammatory cells and fluid from the blood vessels into extracellular tissues lead to a decrease in the paw edema volume of the rat.

Observations based on the scoring of synovitis score from Krenn et al., (2006) which have a sensitivity of 61,7 % and a specificity of 96,1% for this scoring system. It was found that the normal group was not injected complete Freund's adjuvant gives a total score of synovitis  $< 1$  of the examination two observers, which means it does not happen synovitis. While the negative control group, positive and dose variation of extracts *A. conyzoides* leaves were injected complete Freund's adjuvant, gave a total synovitis score of 5-9, means there is high-grade synovitis which is equivalent to rheumatic joint disease. The extract of *A. conyzoides* leaves at doses II and III were significantly ( $p < 0.05$ ) reduce the synovitis score which equivalent to rheumatoid arthritis condition and prevent progress deterioration in the RA which is equivalent to the use of the drug methotrexate.

Synovitis causing activated macrophages in the synovial membrane, over-expression of inflammatory cytokines (including TNF- $\alpha$  and IL-1), chemokines (IL-8) and MMP (Matrix metalloproteinases). TNF- $\alpha$  and IL-1 can activate synovial fibroblasts, triggering the production of MMP and activate the production of other pro-inflammatory cytokines. MMP secreted by chondrocytes can damage cartilage, and the activity of pannus can increase the damage of cartilage to the bone area (McInnes and Schett, 2011). Pannus is invasive of neovascular tissue synovial membrane, especially fibroblasts like synoviocytes which with the help of VEGF (Vascular endothelial growth factor) could damage surrounding tissue.



*A.conyzoides* leaf extract containing flavonoids (quercetin), which can inhibit the proliferation of the synovial membrane through increased synoviocytes apoptosis through inhibition of NF-kB and COX-2 (Durga et al., 2014), so the production and activity of mediator pro-inflammation such as TNF-a and IL-1 are inhibited. Quercetin also inhibits the secretion of VEGF in endothelial cells, thereby inhibiting the formation and development of panus. Quercetin can also inhibit the activity of bFGF (basic Fibroblast growth factor) that helps in the formation panus (Ji et al., 2013).

#### 4. Conclusion

The hydroethanolic extract of *Ageratum conyzoides* L. leaf which containing secondary metabolites mainly flavonoids (quercetin) can inhibit the process of chronic inflammation. It would inhibit the production and activity of pro-inflammatory cytokines, especially TNF- $\alpha$  and IL-1 that played an important role in the anti-inflammatory mechanisms by means inhibition activation of nuclear factor-kappa B (NF-kB). The results of evaluation the effectivity of anti-rheumatoid arthritis in rats showed that the hydroethanolic extract of *Ageratum conyzoides* L. leaf could reduce the volume of paw edema and the synovitis score in rat depending on the dosage. Therefore, the hydroethanolic extract of *Ageratum conyzoides* L. leaf have a potential effect on anti-rheumatoid arthritis by in vivo.

#### 5. Acknowledgment

The authors would also like to acknowledge to Faculty of Pharmacy Universitas Indonesia and the DRPM-UI for providing helpful and facilities to carry out this study.

#### References

- Aletaha D, Kapral T, Smolen JS. Toxicity profile of traditional disease modifying antirheumatic drugs for rheumatoid arthritis. *Ann Rheum Disease*. 2003; 62(5):482-6.
- Awad NE, Kassem HA, Elkhayat ZA, El-Feky AM, Matloub, A.A. Chemical composition and anti-inflammatory evaluation of *Ageratum conyzoides* L. leaves. *Journal of Applied Sciences Research*. 2013; 9 (3): 2126-2134.
- Bellik Y, Boukraa L, Alzahrani HA, Bakhotmah BA, Abdellah F, Hammoudi SM, et al. Molecular mechanism underlying anti inflamantory and anti allergic activity of phytochemicals : an Uptade. *Molecules*. 2013; 18: 322-353.
- Bolon B, Stolina M, King C, Middleton S, Gasser J, Zack D, et al. Rodent preclinical models for developing novel antiarthritic molecules: Comparative biology and preferred methods for evaluating efficacy. *Hindawi Publishing Corporation Journal of Biomedicine and Biotechnology*. 2011; DOI: 10.1155/2011/569068.
- Durga, M., Nathiya, S., Devasena, T. Immunomodulatory and antioxidant actions of dietary flavonoids. *Int Journal Pharm Pharm Sci*. 2014; 6(2): 50-56.
- Hassan MM, Shahid-ud-Daulla AFM, Jahan IA, Nimmi I, Adnan Mansur AA, et al. Anti-

- inflammatory activity, total flavonoid and tannin content from Ethanolic extract of *Ageratum conyzoides* Linn. leaf. *International Journal of Pharmaceutical and Phytopharmacological Research*. 2012; 1 (5): 234-241.
- Ikawati Z. *Farmakologi molekuler target aksi organ dan mekanisme molekularnya*. Yogyakarta : Gadjah Mada University Press; 2014.
- Ji JJ, Lian Y, Huang S, Zhang HJ, Diao YP & Li K. Quersetin : a potential nature drug for adjuvant treatment of rheumatoid arthritis. *Afr. J. Tradit. Complement Altern. Med*. 2013; 10(3):418-421
- Krenn V, Morawietz L, Buemester GR, Kinne RW, Mueller-Ladner U, Muller B, et al. Synovitis score;discrimination between chronic low-grade and high-grade synovitis. *Histopathology*. 2006; 49: 358-364
- McInnes IB, & Schett G. Mechanism of disease the pathogenesis of rheumatoid arthritis. *The New England Journal of Medicine*. 2011; 365: 2205-2219.
- Moura AC, Silva EL, Fraga MC, Wanderley AG, Afiatpour P, Maia MB. Anti-inflammatory chronic toxicity study of the leaves of *Ageratum conyzoides* L. in rats. *Phytomedicine*. 2005; 12 (1-2): 138-42.
- Nair MP, Mahajan S, Reynolds JL, Aalinkeel R, Nair H, Schwartz SA, Kandaswami C. The flavonoid quersetin inhibits proinflammatory cytokine (Tumor necrosis factor-alpha) gene expression in normal peripheral blood mononuclear cells via modulation of the NF-kB sistem. *Clinical and vaccine immunology*. 2006; 13(3):319-328.
- Okunade AL. Review *Ageratum conyzoides* L. (Asteraceae). *Fitoterapia*. 2002; 73: 1-16.
- Rosenbergh, A. E. *Tulang, sendi dan tumor jaringan lunak*. In Kumar V, Abbas AK, Aster JC., Ed. *Buku Ajar Patologi Robbins*. 9<sup>th</sup> edition. Elsevier Saunders: 2013.
- Singh SB, Devi WR, Marina, Devi WI, Swapana N, Singh CB. Ethnobotany, phytochemistry and pharmacology of *Ageratum conyzoides* Linn (Asteraceae). *Journal of Medical Plants Research*. 2013; 7 (8). pp.371-385.